

Introduction

Human Papillomavirus (HPV) is the most common sexually transmitted infection globally, affecting approximately 79 million people in the U.S. While often asymptomatic, HPV can cause various lesions and cancers, including periungual warts that may lead to pain, nail damage, and squamous cell carcinoma (SCC). This case report discusses a rare case of severe condylomas with superimposed SCC on a patient's upper extremities.

Methods

The rare case was identified, and the patient consented to participate in the case report as a deidentified individual. All identifying features were removed to maintain anonymity, and all protected health information was excluded.

Pre-operative presentation

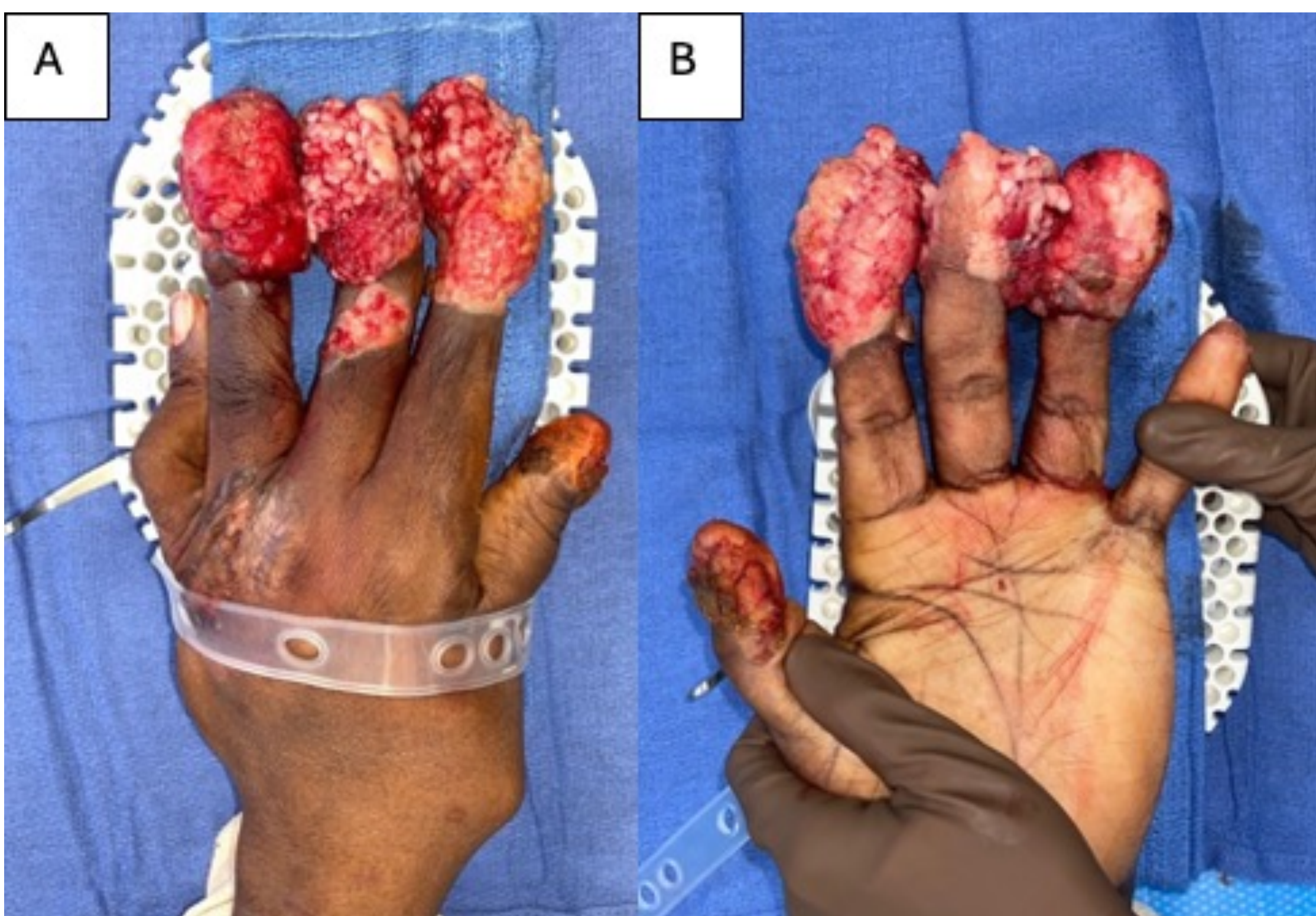


Figure 1: Preoperative presentation of dorsal (A) and volar (B) views of L hand on 10/22/22

Results

A 42-year-old male with cell-mediated immunodeficiency and a long history of disseminated HPV presented with worsening, painful lesions on his hands and feet. His medical history included a failed bone marrow transplant and unsuccessful treatments like intralesional Cidofovir. A multidisciplinary team managed his care, focusing on palliative treatment to alleviate pain and address the risk of malignant transformation. Initial surgery involved amputating the left index and ring fingers and debulking lesions on the left thumb and long finger. Pathology revealed SCC with positive margins, leading to a stage IV SCC diagnosis and initiation of pembrolizumab therapy.

As painful malignant lesions persisted, further surgeries were performed, including the amputation of the right thumb, index, and long fingers, along with excision of lesions on the hand and forearm. The treatment aimed to manage pain, prevent infection, and control cancer spread, with ongoing surgeries to debulk tumors and maintain hand function. Despite positive margins in some resected specimens, palliative debulking and amputations effectively managed symptoms. Ultimately, the final surgical margins were cancer-free following further surgical intervention, suggesting that the combination of palliative surgery and pembrolizumab was effective in controlling the disease. The patient's amputation sites healed well, with no post-surgical complications, indicating successful management of the patient's disease.

Post-operative Images

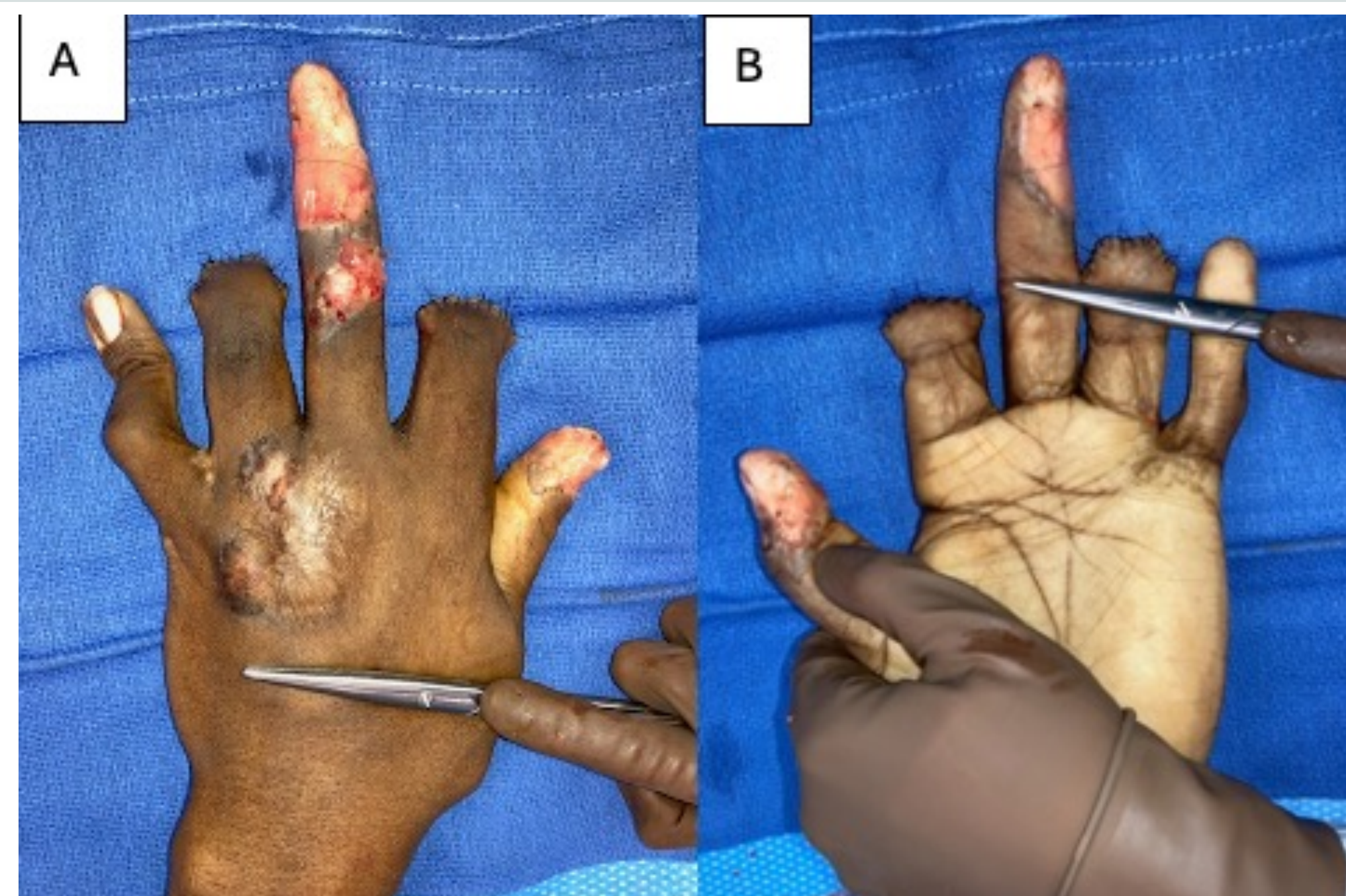


Figure 2: Post-operative images of dorsal (A) and volar (B) L hand following digital amputation of L index and ring fingers, debulked L thumb and L long finger lesions, and integra

Follow-up Images

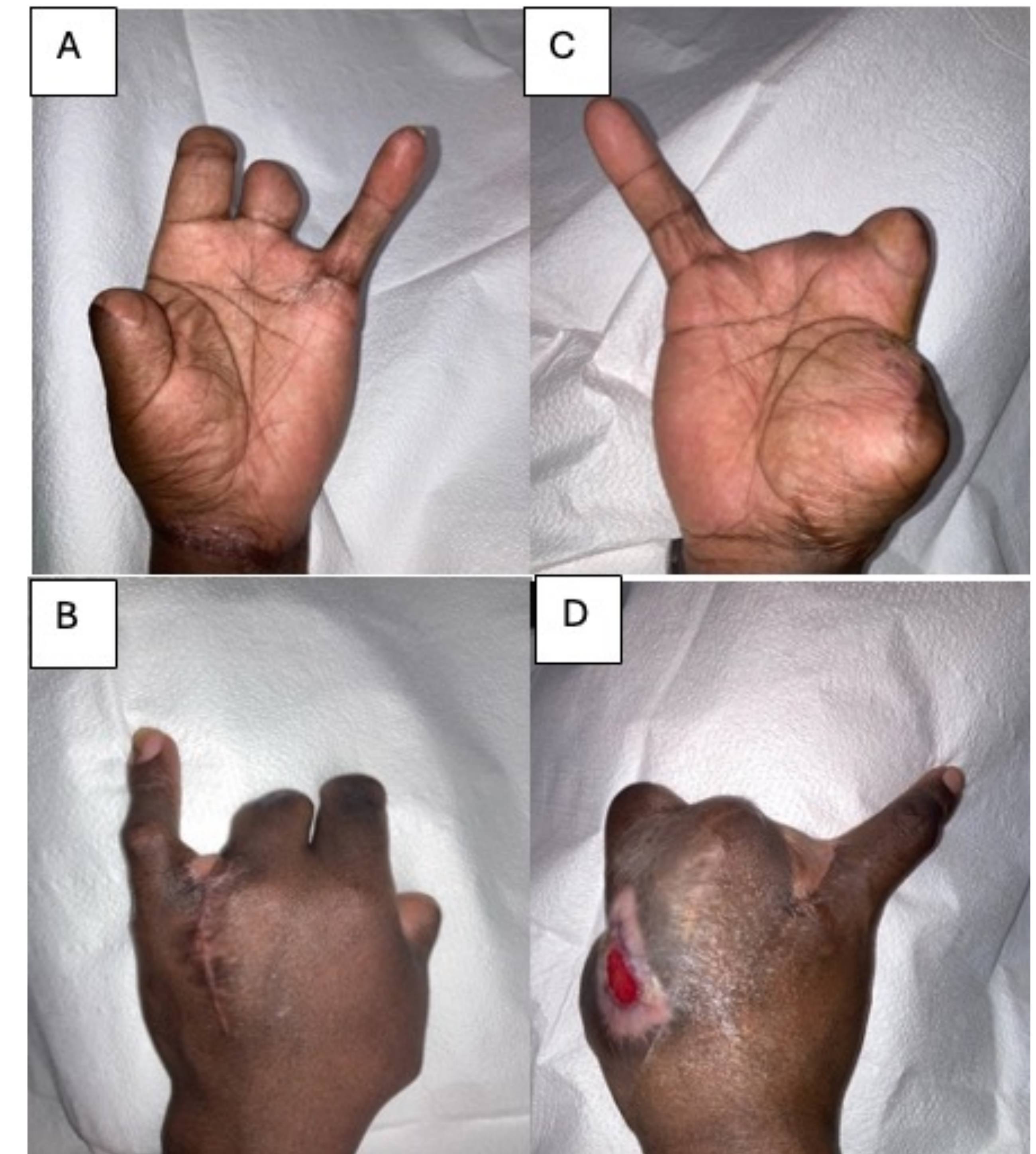


Figure 3: Follow-up images of left hand volar (A) and dorsal (B) and right hand volar (C) and dorsal (D) on 8/8/23

Conclusion

This case highlights a severe stage IV HPV-associated SCC in both hands, where curative treatment was not possible. However, palliative surgeries, including debulking and amputations, were crucial in improving quality of life by preserving hand function, alleviating pain, and managing hygiene issues. This underscores the importance of palliative surgery in enhancing the quality of life for patients with similar conditions.