

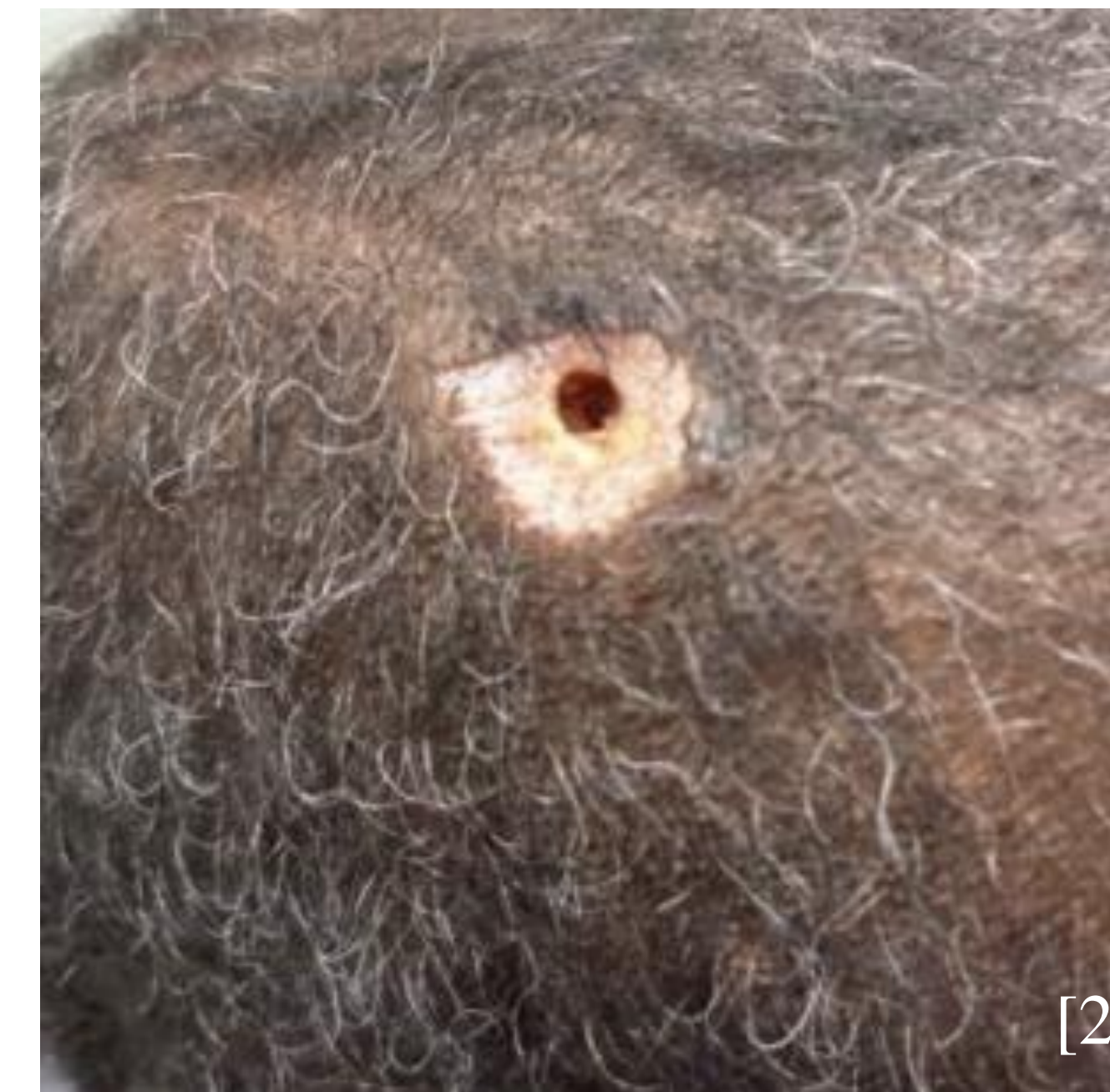
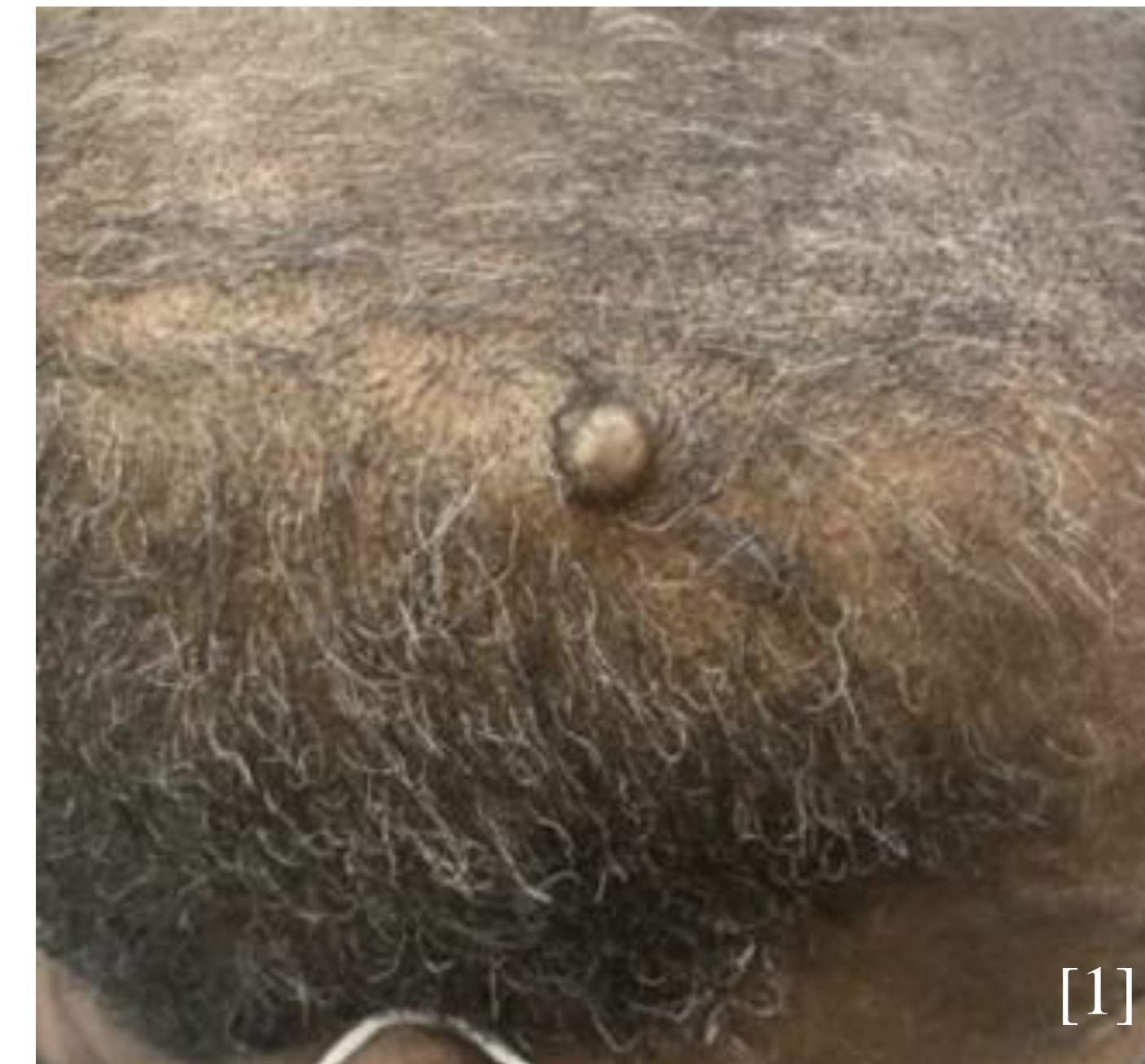Introduction

- Nevus Sebaceous of Jadassohn (NS) is a congenital cutaneous hamartoma that usually appears at birth as a benign plaque on the scalp, face, or neck.
- NS carries a risk of neoplastic transformation, though most secondary tumors are benign.
- Papillary hidradenoma (hidradenoma papilliferum, HP) is a benign tumor that arises from apocrine or anogenital mammary glands, almost exclusively in the perineal region.
- Ectopic HP can occur outside the perineal region, most commonly in men as subcutaneous tumors on the head or neck, but this has rarely been seen within NS.
- This report presents a rare case of NS with a secondary cystic papillary hidradenoma on the scalp, a site with limited apocrine gland distribution.

Case Description

- A 63-year-old male with no prior dermatologic history presented with an enlarging nodule on the right side of his scalp.
- He reported having a thin, raised plaque in the area since childhood, with recent development of a nodule within it.
- He denied pain, pruritus, drainage, or any other symptoms associated with the lesion.
- On examination, a 1 cm, skin-colored, smooth nodule was observed overlying a 2.1 x 1.7 cm hyperpigmented, verrucous, alopecic plaque in the right temporoparietal region (Figure 1).
- A shave biopsy was performed, leaving a tunnel-like opening extending from the dermis into the subcutaneous tissue (Figure 2).
- Histopathology revealed papillomatosis, hyperkeratosis, increased epidermal melanin, sebaceous gland proliferation, ectopic apocrine glands, and ductal hyperplasia, findings consistent with NS (Figures 3-5).
- Additional features of eccrine, apocrine, and papillary hidradenoma were identified, suggesting a hybrid lesion.
- The clinical and histopathological findings were consistent with a diagnosis of Nevus Sebaceous of Jadassohn with secondary cystic papillary hidradenoma.
- Total excision was recommended, but the patient opted for clinical monitoring after discussing risks and benefits.

Clinical and Pathological Images



Figures 1 and 2. Clinical images featuring the (1) initial presentation of a 1 cm nodular growth overlying a hyperpigmented, verrucous plaque and (2) skin findings after shave excision of the nodule.

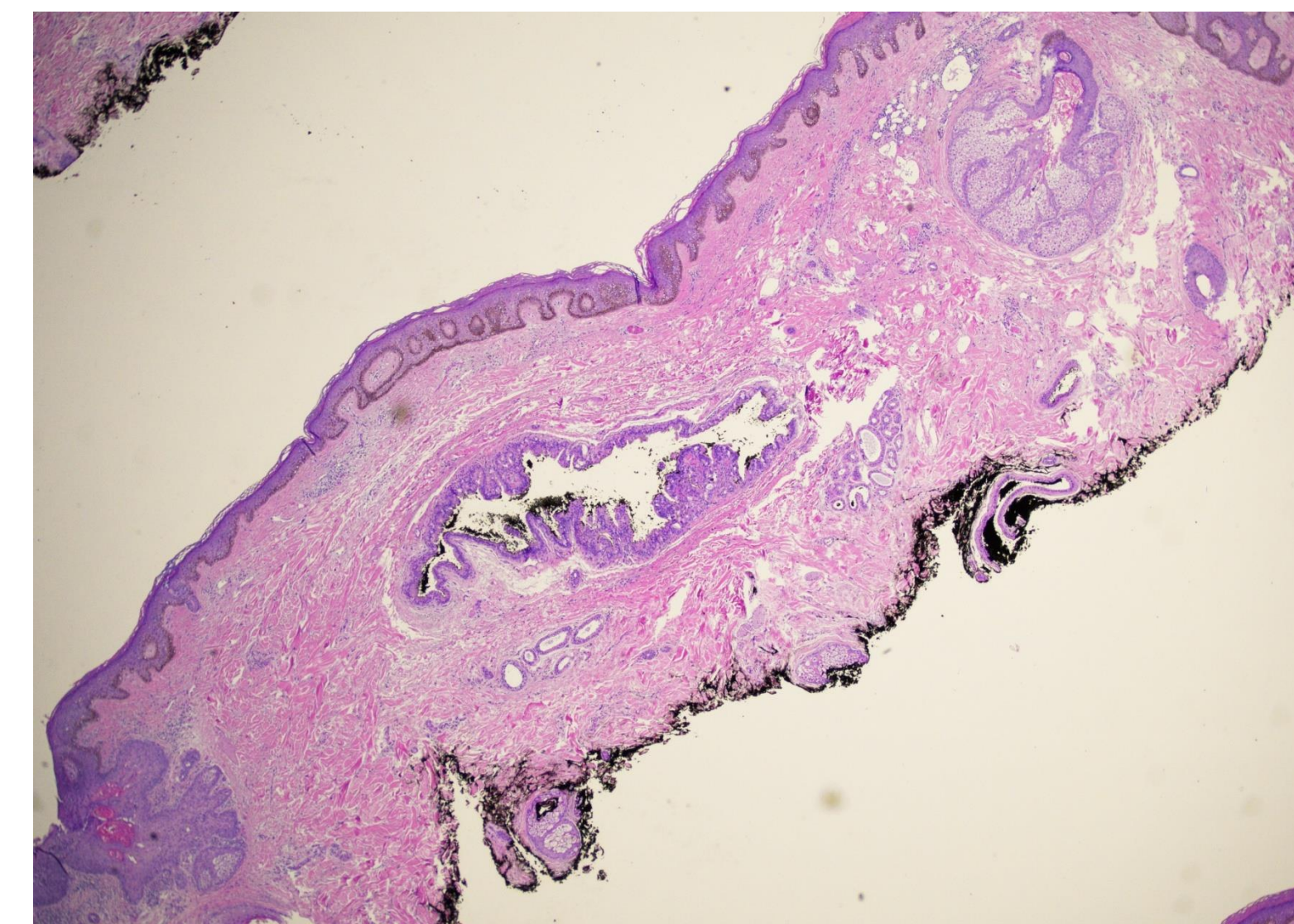


Figure 3. Histologic image of shave biopsy revealing Hidradenoma Papilliferum (HP) with overlying Nevus Sebaceous (NS).

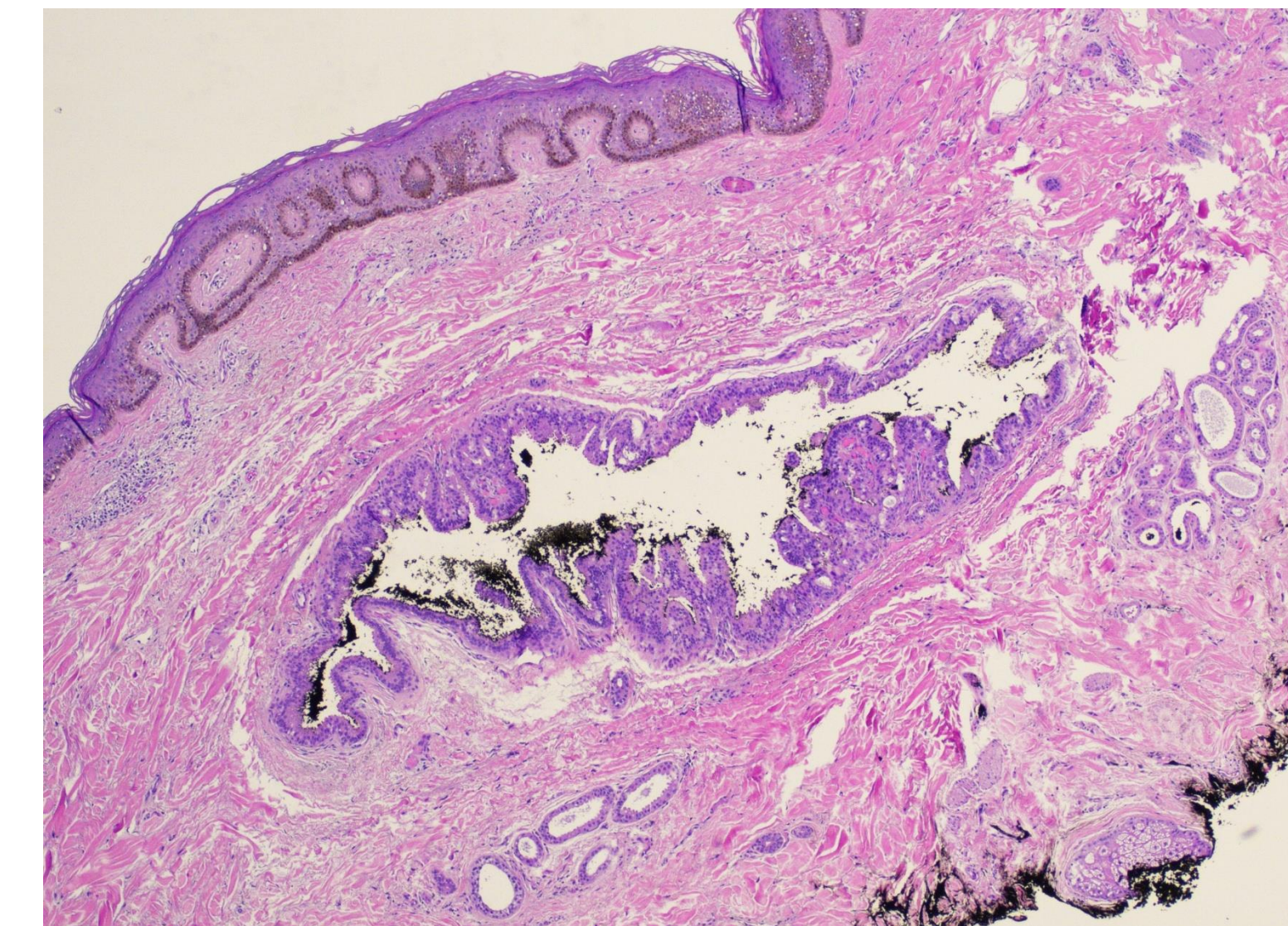


Figure 4. Histologic image with increased magnification of HP.

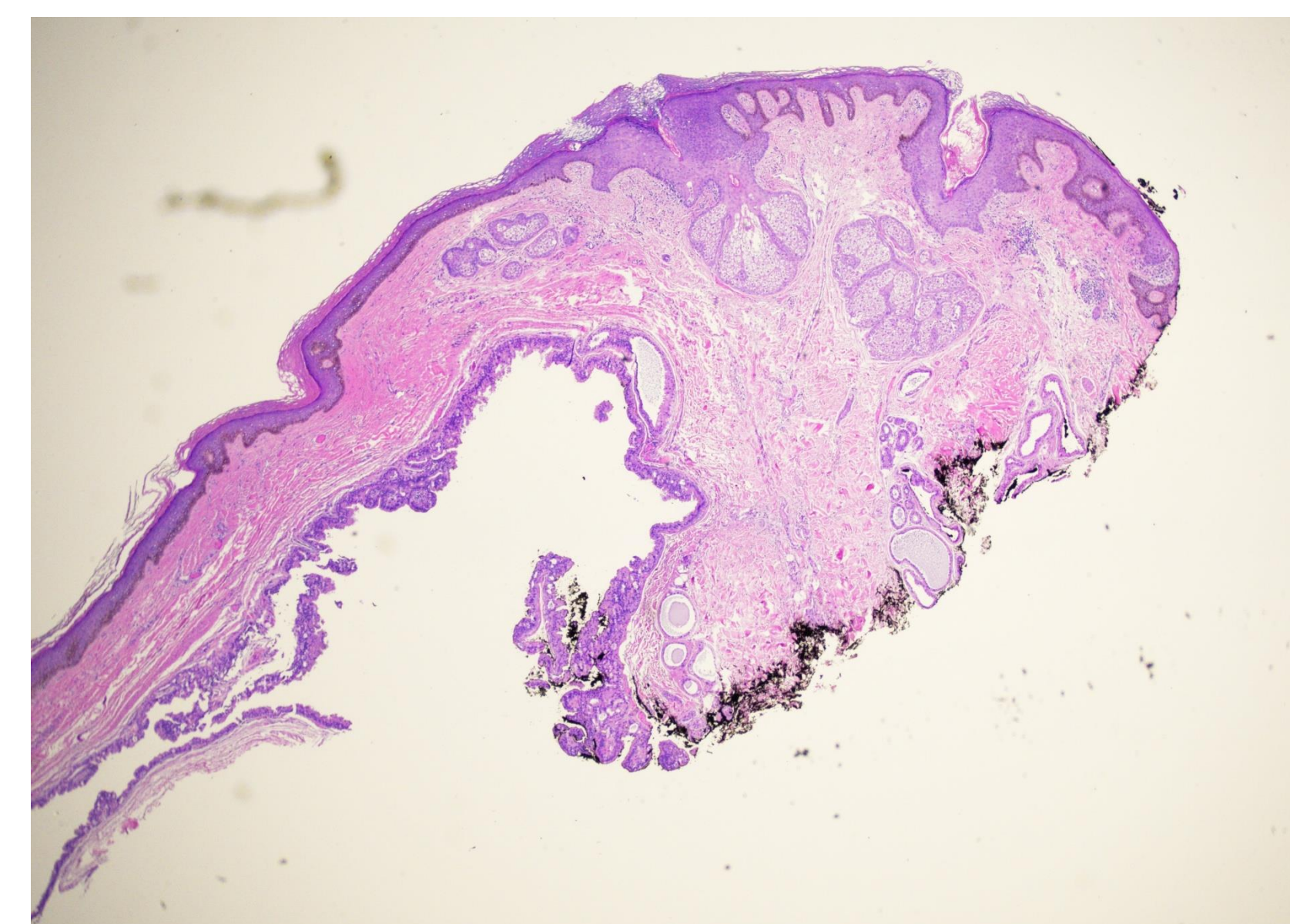


Figure 5. Additional view of histologic image of HP with overlying NS.

Discussion

- Nevus sebaceous of Jadassohn (NS) is a congenital hamartoma involving pilosebaceous units, epidermis, and adnexal structures.
- Histologically, childhood lesions show acanthosis, papillomatosis, and adnexal malformations, with possible presence of ectopic apocrine glands and eccrine hyperplasia.
- During puberty, hormonal stimulation causes benign proliferation of sebaceous and adnexal structures, resulting in lesion thickening and a more verrucous appearance.
- In adulthood, further growth warrants evaluation for secondary neoplasms.
- Secondary tumors arise in ~10–20% of NS cases, with the majority being benign. The most prevalent benign tumors are trichoblastomas and syringocystadenomas.
- Rare ectopic HP can occur in areas with apocrine/eccrine activity, such as axillae, breasts, eyelids, ears, with men more commonly affected in these locations.
- Histologically, these tumors exhibit cystic eosinophilic spaces with papillary and adenomatous structures lined by a double layer of epithelium.
- Although malignant transformation is rare, complete excision is recommended to prevent recurrence or progression.
- Ectopic apocrine glands and eccrine hyperplasia associated with NS may have contributed to the development of this HP and likely increase the overall risk of benign growths within NS.
- By documenting this rare tumor combination, the case adds to the growing understanding of the diverse neoplastic potential of NS.

References

1. Baigrie D, Troxell T, Cook C. Nevus Sebaceous. In: *StatPearls*. StatPearls Publishing; 2024. Accessed October 29, 2024. <http://www.ncbi.nlm.nih.gov/books/NBK482493/>
2. Chauhan H, Tandon P, Potlia I, Jain E. Rare and unusual occurrence of ectopic hidradenoma papilliferum in maxillofacial region. *Journal of Oral and Maxillofacial Pathology*. 2020;24(3):554. doi:10.4103/jomfp.JOMFP_126_20
3. Neto MP da S, Assis BR de, Andrade GR. Sebaceous nevus of Jadassohn: review and clinical-surgical approach. *Anais Brasileiros de Dermatologia*. 2022;97(5):628-636. doi:10.1016/j.abd.2021.11.001
4. Cribier B, Scrivener Y, Grosshans E. Tumors arising in nevus sebaceous: A study of 596 cases. *J Am Acad Dermatol*. 2000;42(2 Pt 1):263-268. doi:10.1016/S0190-9622(00)90136-1.
5. Shimon SV, Alenezi SM, Camela E, Maderal AD, Romanelli P. A Rare Case of Ectopic Hidradenoma Papilliferum of the External Auditory Canal. *Cureus*. 2024;16(5):e61237. doi:10.7759/cureus.61237
6. Kondo RN, Melhado IP, Moreira CR, Crespigio J. Ectopic hidradenoma papilliferum. *Anais Brasileiros de Dermatologia*. 2018;93(3):474. doi:10.1590/abd1806-4841.20187572